

Correspondence

Critical Analysis of the Staged Laparoscopic Roux-en-Y: A Two-Stage Operation to Diminish the Size of the Liver in Super-Obese Patients

To the Editor:

We read the interesting paper *Staged Laparoscopic Roux-en-Y: A Novel Two-Stage Bariatric Operation as an Alternative in the Super-obese with Massively Enlarged Liver*, by the renowned Ninh T. Nguyen, with M. Longoria, D.V. Gelfand, A. Sabio, and S.E. Wilson.¹ The enlarged liver is a major concern for the bariatric surgeon. The effort to create alternatives to operate on patients with this problem is very important. The technique described is a very intelligent idea, but the pioneers have to overcome the uncertainty with this new procedure.

Some points in this article are controversial. This new technique is not a simple and easy operation; severe complications can occur in super-obese patients submitted to this procedure. The first stage of the procedure consists of three main steps: 1) gastric partition; 2) gastrojejunostomy (Figure 1). The latter stage of the procedure is similar to the biliopancreatic diversion with gastric preservation as performed by Domene in Brazil,² differing in the length of the alimentary and

biliopancreatic limbs. The second stage of the procedure consists of a sleeve gastrectomy (Figures 2A-C) performed 6 to 12 months after the first stage. These several steps make this operation as complex as many bariatric operations. The laparoscopic RYGBP in the super-obese is associated with higher morbidity and mortality as demonstrated by Artuso et al,³ and the two-stage procedure probably has the same outcome. The operated individual may develop several complications in any of the three steps, e.g. 1) acute gastric dilatation, 2) bleeding in the staple-line, 3) intra-abdominal bleeding, 4) gastrojejunostomy and jejunojejunostomy dehiscence, 5) gastrojejunostomy fistula, 6) intestinal obstruction. If this technique is compared to the sleeve gastrectomy, the latter has less complications and is a faster procedure. Surgical time is very important in the super-obese, preventing complications related to longer operations such as rhabdomyolysis.⁴ The authors perform the gastrojejunal anastomosis low on the lesser curvature, and in doing that, they create a longer gastric pouch. In the future, lengthening can defeat the weight loss from the non-banded gastric bypass, so that the suggested first stage should have a smaller pouch. Another problem in the super-obese is the thickened mesocolon and its weight during creation of the retrocolic tunnel;³ this difficult task can be solved if the gastrojejunostomy is performed ante-colic ante-gastric.

The authors note that “the primary limiting factor making laparoscopic gastric bypass challenging in the super-obese is the volume of the left lobe of the liver”. Many surgeons have good results with a diet with a minimum amount of carbohydrates for 1-2 months before operation which diminishes the thickened lobe of the liver. Even if the liver is unexpectedly large when one passes the laparoscope, the

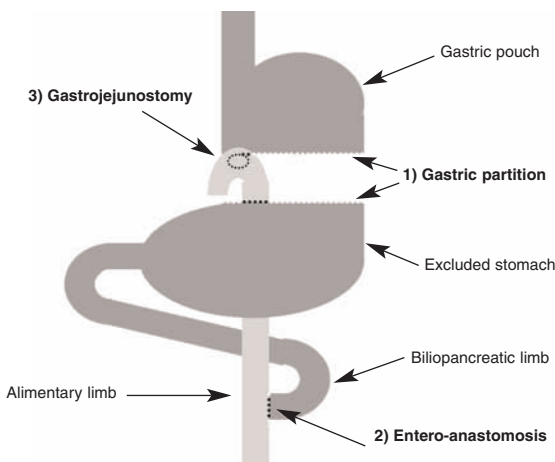


Figure 1. First stage of procedure of Ninh et al¹ – the 3 steps.

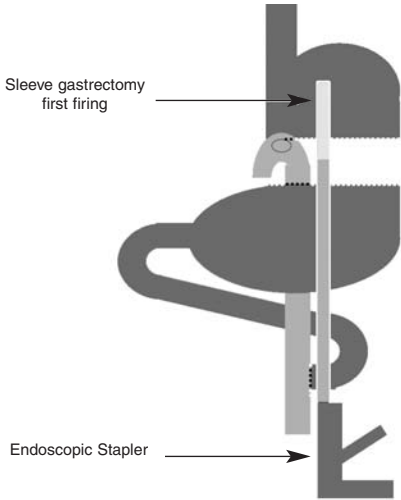


Figure 2A. Second stage – gastrectomy initiation.

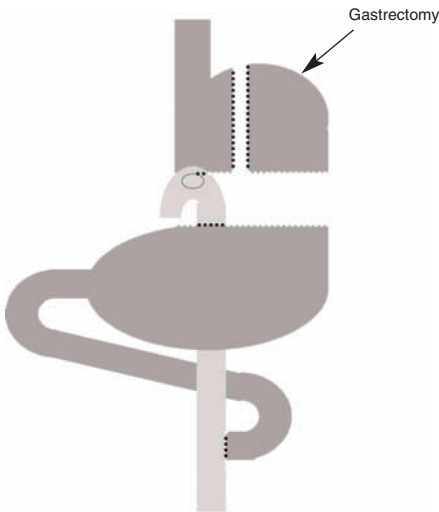


Figure 2B. Second stage – Completion sleeve gastrectomy.

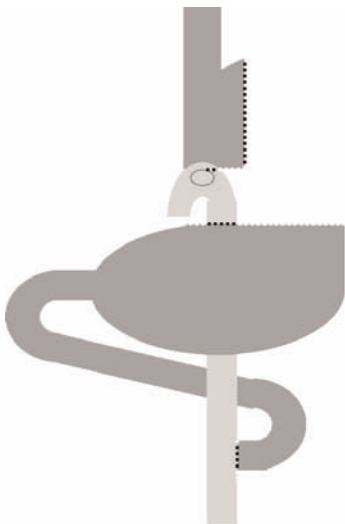


Figure 2C. Second stage – RYGBP final result.

surgeon can stop the procedure and operate 1 to 2 months after the dietetic measures are implemented.

The major hazard when operating on the super-obese, is that when the patient has any complication, there may not be sufficient reserve (pulmonary, cardiovascular, renal, immunologic) to survive the difficulty, which is the rationale for the patient to lose enough weight preoperatively to perform the bariatric operation with less risk. The frequently used measures to achieve this are: 1) low carbohydrate diets, 2) intensive multidisciplinary medical regime, 3) in-hospital diet, 4) intragastric balloon and 5) sleeve gastrectomy.⁵ Some authors cite preliminary gastric banding but this should be a procedure for all life.

During the clinical evaluation if the patient has an enlarged liver demonstrated by the sonography, our bariatric surgery division uses the routine shown in Figure 3 for diminishing the size of the organ.

It is more worrisome if the patient is male with a BMI >50, and has co-morbidities such as respiratory (sleep apnea, Pickwickian syndrome, dyspnea and fatigue), coronary artery disease, asthma, diabetes, and chronic venous insufficiency. We should assure that these patients lose weight before surgery. In our practice, we send them to a medical SPA first, and if the problem is not solved we use the intragastric balloon (a very expensive procedure). We have achieved success in the super-obese that underwent these strategies.

Another concern is to convince the insurance companies to perform two operations to treat morbid obesity. In Brazil and in the US, it is becoming difficult

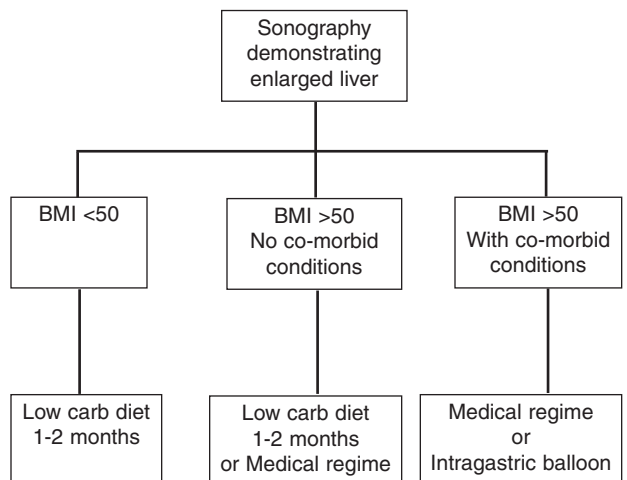


Figure 3. Algorithm for dealing with a very large liver.

even to convince the corporations to pay for the single operation. The second operation at a later date will also expose the patient to general anesthesia a second time, which leads to increased costs⁶ and possibly a greater chance of complications than one procedure.

The staged laparoscopic Roux-en-Y (first stage) seems to be as radical as the traditional laparoscopic gastric bypass, and other less complicated measures can be done to perform the RYGBP without an enlarged liver. Patient data will show the efficacy and complication rate of this innovative technique in the future. Probably in the hands of the proficient Dr. Nguyen the complication incidence will be very low.

**João Eduardo Marques Tavares de Menezes
Ettinger, MD^{1,2}; Euler Azaro, MD, PhD^{1,2};
Carlos Augusto Bastos Mello, MD¹;
Edvaldo Fahel, MD, PhD^{1,2}**

¹Bariatric Surgery Division, Hospital São Rafael & Hospital Cidade, ²Department of Surgery Escola Bahiana de Medicina, Salvador, Bahia, Brazil
E-mail: ettinger@lognet.com.br

References

1. Nguyen NT, Longoria M, Gelfand DV et al. Staged laparoscopic Roux-en-Y: a novel two-stage bariatric operation as an alternative in the super obese with massively enlarged liver. *Obes Surg* 2005; 15: 1077-81.
2. Domene CE, Rasera I Jr., Volpe P et al. Video-laparoscopic biliopancreatic diversion with gastric preservation: preliminary results. *Obes Surg* 2002; 12: 521 (abst P145).
3. Artuso D, Wayne M, Kaul A et al. Extremely high body mass index is not a contraindication to laparoscopic gastric bypass. *Obes Surg* 2004; 14: 750-4.
4. Ettinger JEMT, Santos Filho PV, Azaro EM et al. Prevention of rhabdomyolysis in bariatric surgery. *Obes Surg* 2005; 15: 874-9.
5. Miline L, Strong V, Gagner M. Laparoscopic sleeve gastrectomy is superior to endoscopic intragastric balloon as a first stage procedure for super-obese patients (BMI ≥ 50). *Obes Surg* 2005; 15: 612-7.
6. Farkas DT, Vemulapalli P, Haider A et al. Laparoscopic Roux-en-Y gastric bypass is safe and effective in patients with a BMI >60 . *Obes Surg* 2005; 486-93.

Reply:

We thank Dr. Ettinger and colleagues for their comments which raised some interesting points. They believe that our new laparoscopic bariatric procedure is not a simple and easy operation – and they are right. We have to reiterate that there is no simple, easy bariatric operation in the super obese and agree that any procedure in this subset of patients has its inherent advantages and disadvantages.

We wish to emphasize that our technique is not truly novel, but more accurately, a variation of an existing operation. We continue to perform the conventional Roux-en-Y gastric bypass in the super obese; however, in the rare instance where we are faced with a patient who has a greatly enlarged left hepatic lobe or a massive omentum obscuring visualization of the gastric cardia, gastroesophageal junction and angle of His, we suggest alteration of the Roux-en-Y gastric bypass to a two-stage operation. In the first stage, a larger than usual gastric pouch with a low gastrojejunostomy is constructed so as to relieve tension on the anastomosis. The rationale for this variation is to eliminate the difficulty, indeed hazard, of operating within an anatomical region notorious for limited visualization of the gastric cardia and angle of His. In our experience, construction of the jejunojejunostomy has not been a limiting factor even in the super obese. The second stage is performed 6-12 months after the first stage and consists of a completion sleeve gastrectomy to end up with a small, elongated gastric pouch. The second stage procedure is relatively easy because both the size of the liver and omentum have now been reduced with weight loss. Dr. Ettinger must appreciate that we only advocate this two-stage procedure in a very small subset of super-obese patients and do not recommend the routine use of this procedure.

Ettinger and colleagues also noted that sleeve gastrectomy is a faster procedure that has fewer complications than our proposed technique. The largest series of sleeve gastrectomies published by Schauer et al¹ reported a leak rate of 2% and a gastric obstruction rate of 4%. Their experience confirmed that laparoscopic sleeve gastrectomy is not a benign procedure and may be associated with life-threatening complications such as intestinal leakage.